

COLOCALIZED NEVUS DEPIGMENTOSUS AND LENTIGINES.

A 3-year-old boy presented from the age of 1 year a hypopigmented area with indented borders on the left mandibular region and chin. Later on at the age of 2 numerous hyperpigmented punctiform spots appeared exclusively on the hyperpigmented area. With sun exposure the white area did not redden and did not burn. On physical examination (Fig. 1), a white, band-like, 1-4 centimeters large and about 10 centimeters long patch affects the left cervical region, starting 3 centimeters under the ear. It runs under the horizontal branch of the lower jaw and ends on the chin till 2 centimeters under the left lower lip. About 30 more or less brownish, but always darker than normal skin, 1-3 millimeters in size, roundish, dots affect the hypopigmented area, never involving the normally pigmented surrounding skin.

The dermoscopic examination (Fig. 2) shows 1-3 millimeters in size hyperpigmented lesions with a barely visible pseudonet, leading to the final diagnosis of **colocalized nevus depigmentosus and lentigines**.

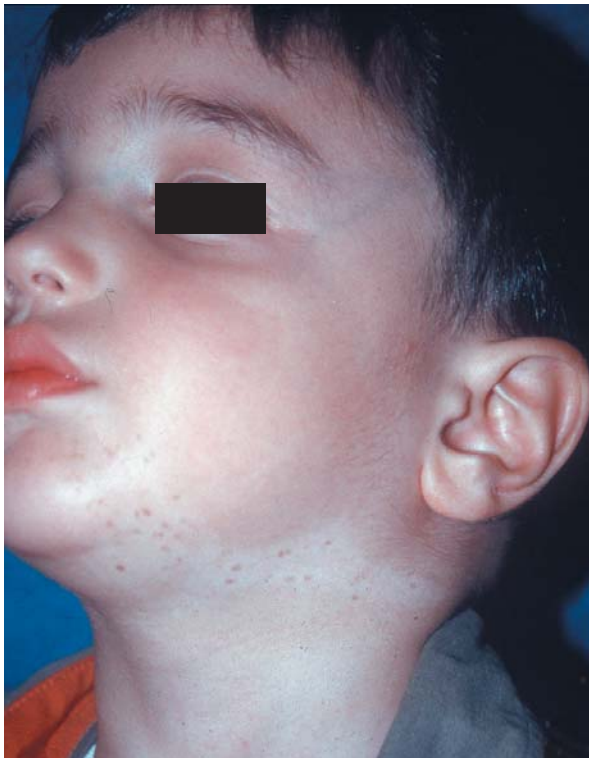

Fig. 1

Until now 4 cases of **colocalized nevus depigmentosus and lentigines** have been reported (1, 2, 3). The theory of twin spots does not apply to colocalized nevus. Two hypotheses were suggested for the latter (2). The first one, which applies to larger lesions such as syndrome of Ito, hypothesizes that a mutational event occurring in the first 4 weeks, when the embryo is a single developmental field, leads to a polytopic malformation, namely more associated malformations. In our case, characterized by small nevi affecting the same melanocytic function, is more probable the hypothesis (2) of an initial mutation responsible for nevus depigmentosus, which is followed by a reverse mutation of a gene involved in the pigmentation. The latter could restore, although incompletely, the pigmentation. Finally, sun exposure is not responsible for lentigo formation in nevus depigmentosus, thus not supporting the hypothesis that lentigines occurred due to this mechanism in our case.

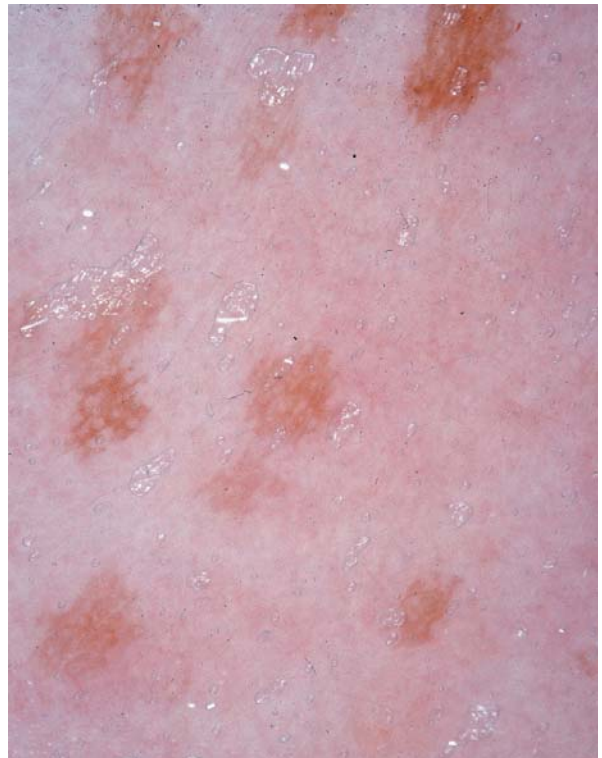


Fig. 2

References

- 1) Bologna J.L., Lazova R., Watsky K. - The development of lentigines within segmental nevus depigmentosus. *J. Am. Acad. Dermatol.* 39, 330-3, 1998.
- 2) Jagia R., Mendiratt V., Koranne R.V., et Al. - Colocalized nevus depigmentosus and lentigines with underlying breast hypoplasia: A case of reverse mutation? *Dermatology Online J.* 10 (1), 12, 2004.
- 3) Khumalo N.P., Huson S., Burge S. - Development of lentigines within naevoid hypopigmentation. *Br. J. Dermatol.* 144, 188-9, 2001.